

White Paper

Quantifying Heart Valves: From Diagnostic to Personalized Valve Repair

Tommaso Mansi, Ph.D.
Helene Houle, BA, RDCS, FASE
Ingmar Voigt
Michael Szucs, BS
Elizabeth Hunter, RDCS
Saurabh Datta, Ph.D
Dorin Comaniciu, Ph.D.

Table of Contents

1. Introduction	3
2. From 3D TEE to Comprehensive 3D Valve Model	4
2.1. Detailed Modeling of Left Heart Valves	4
2.2. Patient Specific, Efficient Detection and Tracking of Valves	6
2.3. Refinement with Intuitive Editing of Valve Models.	6
2.4. Quantitative Valve Assessment using eSie Valves.	7
3. Clinical Applications.	8
3.1. Transcatheter Aortic Valve Replacement (TAVR)	8
3.2. Surgical Mitral Valve Repair	8
3.3. Interventional Mitral Valve Therapy	10
3.4. Other Applications	11
Mitral Valve Stenosis.	11
Rheumatic Valve Disease	11
Barlow Mitral Valve Disease	12
Aortic Valve Regurgitation and Dilated Aortic Root	12
References	14
Recognitions	15

1. Introduction

Valvular heart disease affects 2.5% of the global population, with 200,000 valve repairs performed per year in the United States and Europe. The gold standard for valve repair or replacement is through complex open heart surgery. As a result, valve therapies are among the most expensive (average cost of \$164,238) and riskiest (average in-hospital death rate of 3.36%) cardiac procedures.¹ Surgeons need to acquire very specific reconstructive skills, accurately assess valve tissue, and predict valve function post repair, while operating on a depressurized heart. Since these skills can only be learned through experience, clinical guidelines² introduced the concept of reference centers, where a high volume of valve repairs are performed.

Addressing the challenges of valve diagnosis and treatment requires advanced imaging technologies to visualize valve physiology (anatomy and flow) and reliably quantify its anatomy and dynamics. Current systems only allow high frame-rate valve imaging by stitching sub-volumes over several heartbeats. This inevitably introduces stitching artifacts, prevents the precise evaluation of valve dynamics, and can hinder the imaging quality if the patient suffers from arrhythmias. Similarly, existing valve segmentation solutions are still manual. Modeling a valve can take several minutes and be prone to user variability, which is why quantitative 3D valve anatomy assessment is still a clinical research topic and not yet mainstream.

The eSie Valves™ advanced analysis package sets a new standard in valve assessment. In combination with the new Siemens Z6Ms transesophageal probe, it enables the volumetric visualization of the anatomy (3D B-mode) and blood flow (3D volume color Doppler) simultaneously, in real-time, at high temporal resolution, without stitching. The eSie Valves package enables comprehensive modeling of the mitral valve and aortic valve on any image of the cardiac cycle in less than five seconds from

initial mouse click to measurement output. Combined with an intuitive manual editing interface, a fully reliable valve model can be obtained in just a couple of minutes. Sixty-two different measurements are automatically available for diagnosis, intervention, and surgery planning. With the eSie Valves package, valve quantification becomes reproducible, robust, and efficient.



Quantification with the eSie Valves package is made possible by the new True Volume TEE Transducer (Z6Ms). The Z6Ms represents the latest generation in volume imaging, providing clinically relevant volume sizes and volume rates. The Z6Ms array is built with 2,304 elements and utilizes the power of up to 64 parallel beams for the acquisition of volume B-mode and volume color Doppler at high frame rates. All of this equates to a simpler workflow without the need for conventional stitching, improved user control, and flexibility in Bi-plane+ imaging. It is the key enabler for the eSie Valves package. The Z6Ms has been designed with several thermal management innovations that help achieve uninterrupted imaging, higher sensitivity, and higher volume rates. In addition, the transducer is fully EMI shielded for low interference to devices (such as electrocautery knives) during procedures. As a result, key imaging modes, including volume B-mode and volume color Doppler, are minimally affected and clinically usable. The Z6Ms also includes programmable Smart Buttons that allow the user to customize shortcuts for up to four separate system controls such as clip capture, color Doppler On/Off, and image plane rotation.

2. From 3D TEE to Comprehensive 3D Valve Model

The eSie Valves package relies on advanced machine learning technology to efficiently estimate a comprehensive model of the mitral and aortic valves from 3D transesophageal echocardiographic (TEE) images. Intuitively, a surface model of the valves is fitted to a TEE image using knowledge learned from a large database of annotated (expertly traced, labeled, datasets) images (Section 2.1). For dynamic analysis, a tracking algorithm is employed to estimate a moving valve model throughout the cardiac cycle while leveraging the temporal information for increased accuracy (Section 2.2). The user is offered the possibility to interactively edit each element of the valves model, whenever necessary (Section 2.3). Once the valve is properly segmented, key measurements are calculated automatically and displayed to the user for quantitative valve analyses (Section 2.4).

2.1. Detailed Modeling of Left Heart Valves

The eSie Valves package relies on a detailed representation of the Aortic and Mitral Valves (Figure 1), as previously described in the literature.^{3,4,5,6,7} In brief, each valve is parameterized by three levels of details. The first one defines the region of interest (ROI), where the valve is located within the image, namely valve position (center of the ROI), scale (size of the ROI), and orientation (Figure 1a). Key anatomical landmarks are then defined within the ROI (second level of details). These landmarks are anatomically unique and can be identified in the images. For the mitral valve, these landmarks are the two trigones and the two commissures. For the aortic valve, the landmarks are the three commissures, the three leaflet hinges, and the two ostia (Figure 1b). The landmarks are labelled in the eSie Valves package, making their identification easier for non-experts (Figure 2). Finally, valve surface models (mitral leaflets, aortic leaflets, and aortic root) are represented, passing through the landmarks⁶.

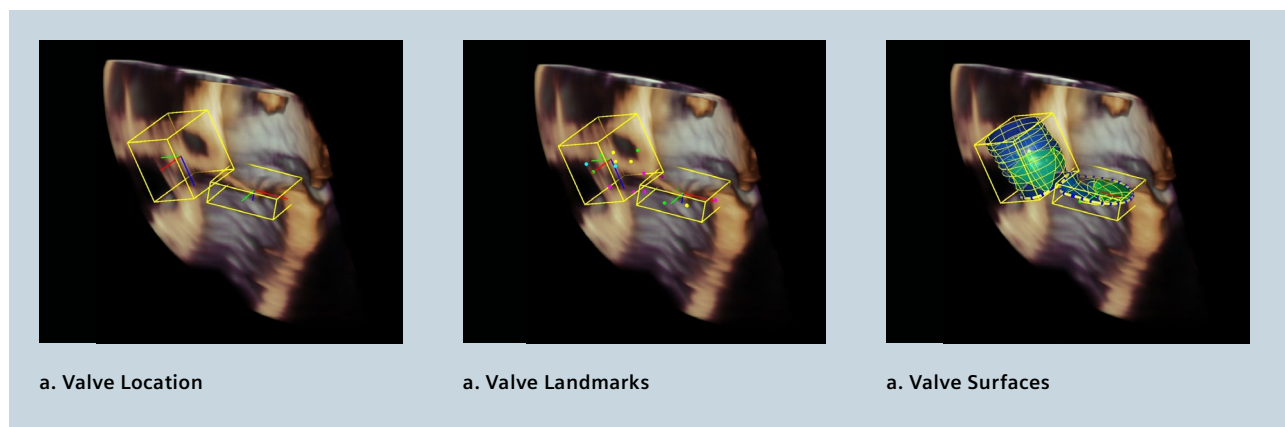


Figure 1. Multi-level representation of the aortic and mitral valves.

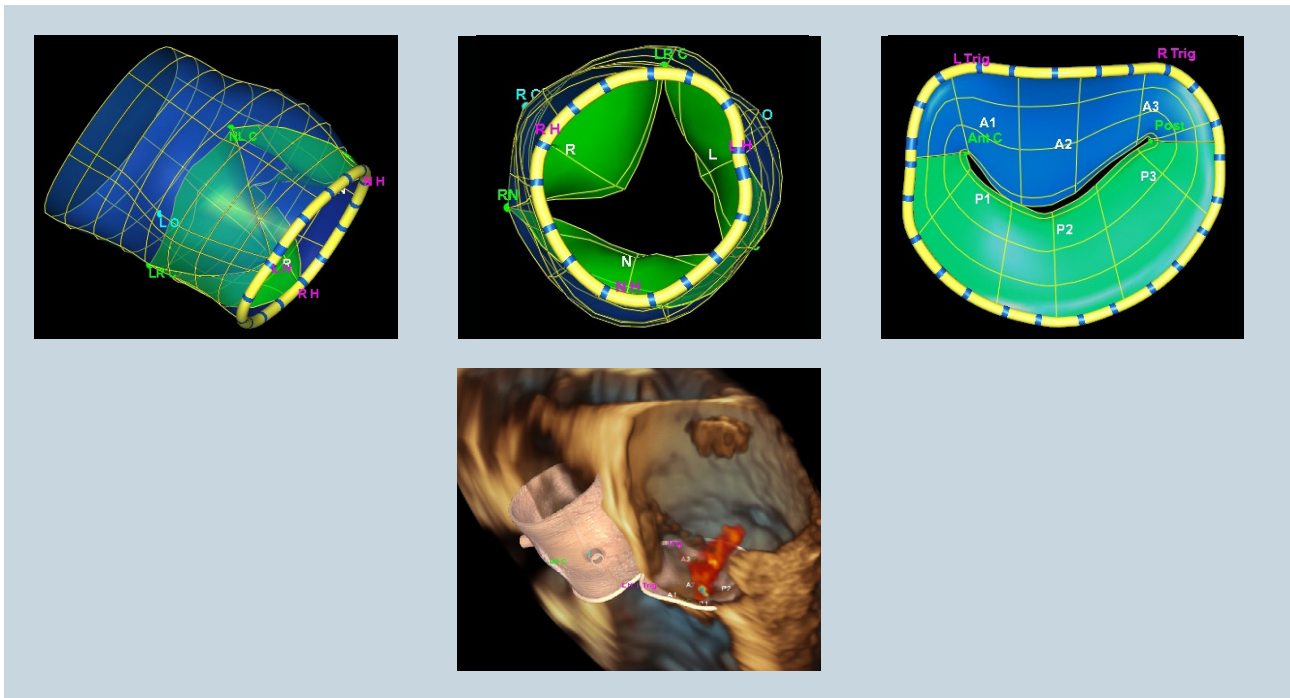


Figure 2. Top row, from left to right: views of the aortic and mitral valve showing the labelled anatomical landmarks. Bottom panel: Valve models in realistic rendering display with underlying image and labels.

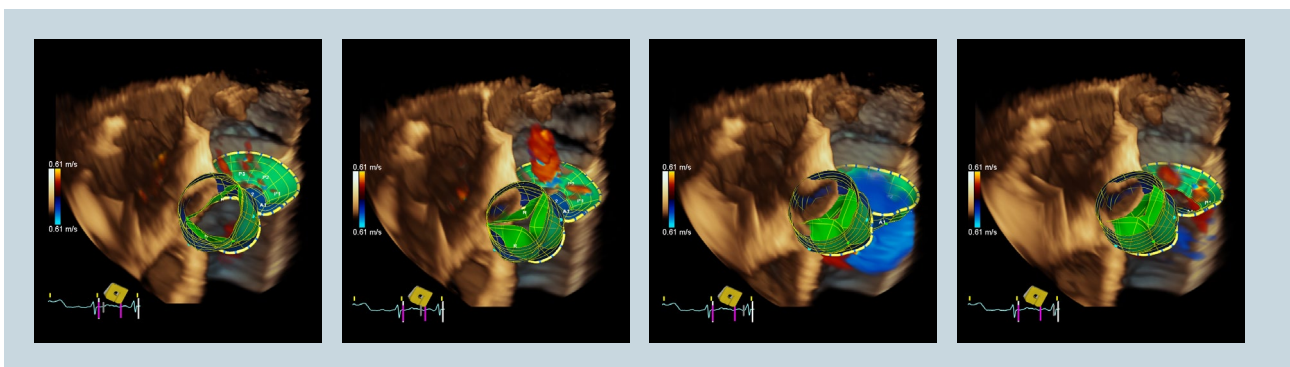


Figure 3. Example of tracked mitral and aortic valve models on several frames.

2.2. Efficient, Patient-Specific Detection and Tracking of Valves

The valve model described in the previous section is fitted to the patient data through detection and tracking. The static workflow enables the user to detect the aortic or mitral valve in the current displayed frame. Advanced machine learning techniques are employed for robust estimation, as previously described in more detail in the literature.^{3,4,5,6,8,9} A large database of annotated images is used to train detectors that are then applied to any new images to estimate the model in seconds (see Section 2.3). As a result, the software provides a robust valve model based on knowledge-based algorithms, which are customized to the specific features in the individual patient’s anatomy.

The dynamic workflow allows automatic tracking for the valve of interest up to three heartbeats, which are selected by the user. Valve tracking consists of estimating the model on several consecutive frames while leveraging the temporal information to increase the robustness of the estimation process. Frame-by-frame detectors are

combined with a speckle tracking algorithm and a motion model to estimate the position of the valve in the dynamic sequence.

2.3. Refinement with Intuitive Editing of Valve Models

While the automatic detection and tracking algorithms enable comprehensive valve modeling in seconds per TEE frame, the eSie Valves package also provides a powerful valve model review and editing mode to interactively adjust the model whenever needed. Despite the complexity of the valve anatomies, a valve can be completely edited in a couple of minutes, including annulus, leaflets, and root. This is achieved by the tight combination of tailored editing views and smart mesh editing. As a result, experts can further refine the patient-specific model to include unique features that represent patient anatomy, function, and disease.

The eSie Valves package offers various editing views (Figure 4) for fast review and editing. The views are automatically defined based on the model (e.g., parallel cuts or rotational cuts). The user can then seamlessly edit

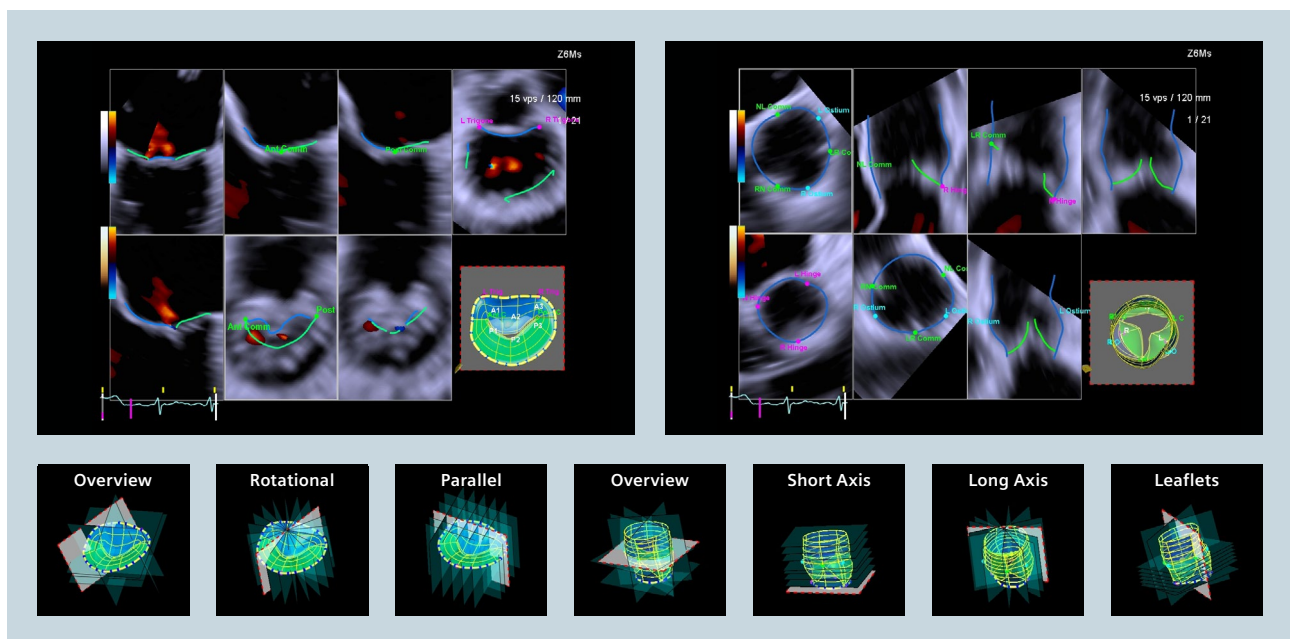


Figure 4. Automatic valve views for efficient and intuitive editing (left panel: Aortic Valve, right panel: Mitral Valve). A screenshot of the eSie Valves package is displayed, along with the different editing view planes for each editing mode (four for the AV, three for the MV).

valve landmarks and surfaces by clicking and grabbing the model. In the background, comprehensive algorithms are applied to ensure the edited valve stays physiological. For instance, constraints make sure leaflets are always connected between each other and that surface and landmarks are always attached. These advanced processing capabilities are available at every editing manipulation, offered in real-time, and completely invisible to the user. As the valve is edited, the views are updated to reflect the new configuration and guide the user toward the observed valve location. The user can also scroll through each predefined viewing plane for finer editing if desired.

2.4. Quantitative Valve Assessment using the eSie Valves Package

The eSie Valves package comes with a comprehensive set of measurements calculated automatically from the valve models. In total, 62 different measurements can be obtained with one click and pre-grouped into three categories: diagnosis, intervention, and surgery, according to the most recent clinical literature. The user can also configure the measurement groups based on clinical applications. In the diagnosis category, some mitral valve measurements include mitral annulus diameters, perimeters, area, inter-trigonal distance, valve orifice area, and intercommissural distance (Figure 5). For each measurement, visual cues are rendered on the 3D model for verification, thus increasing the clinician’s diagnostic confidence (Figure 6).

In summary, only a couple of minutes are required to obtain a 3D TEE sequence, detect a valve, and get all the relevant measurements for valve diagnosis and therapy planning. As a result, the eSie Valves package can help streamline and simplify the clinical management of valve disease, bringing reproducible measurements to the bedside or even in the OR.

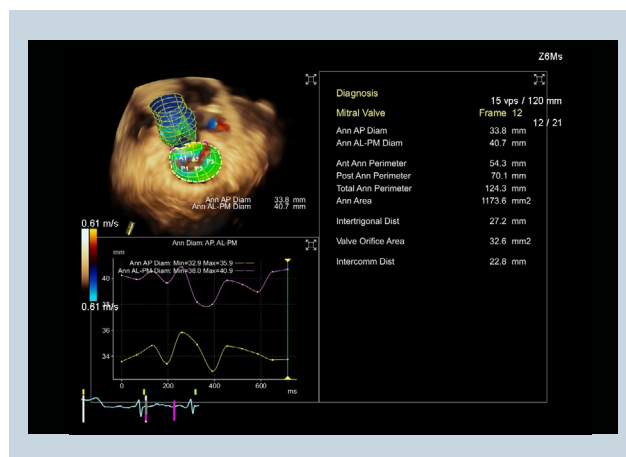


Figure 5. Diagnostic measurements related to the mitral valve. The top left quadrant displays the valve model with measurement visual cues. The bottom left quadrant reports the variation of the selected measurement over time. Finally, the right quadrant reports the predefined set of measurements most often used for diagnostic valve assessment. All the measurements are calculated automatically from the valve model.

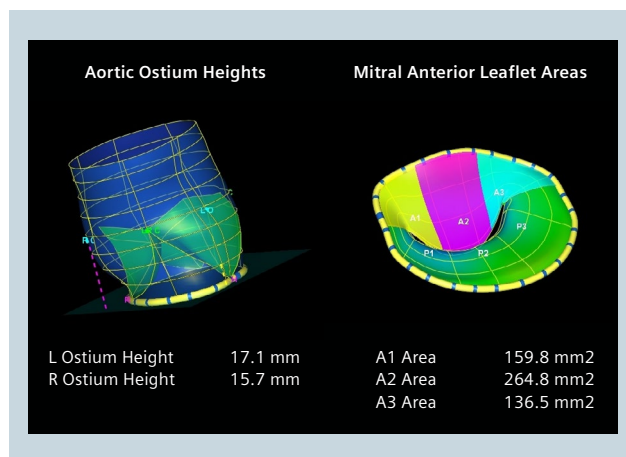


Figure 6. Example of measurement visual cues. On the left, the dashed purple line illustrates the segment used to calculate the right ostium height. On the right, the yellow, purple, and blue areas illustrate the regions of the anterior leaflet used to calculate the A1, A2, and A3 areas respectively.

3. Clinical Applications

3.1. Transcatheter Aortic Valve Replacement (TAVR)

A common use of 3D TEE is during TAVR procedures where the native valve is replaced by a prosthetic device.

The sizing of an aortic annulus (AA) is an important step in ensuring a successful TAVR procedure. According to Ngernsritraku et al.,¹⁰ previous studies have shown that TEE measurements potentially underestimate the aortic annulus when compared with multi-detector computer tomographic (MDCT) sizing. To test the accuracy of the eSie Valves package and True Volume TEE, these studies compared automated measurements using the eSie Valves package with MDCT to determine whether using 3D TEE data selects the same valve size as MDCT.

The study¹⁰ included 40 severely symptomatic aortic stenosis patients who had both 3D TEE (Z6Ms TEE) and contrast MDCT prior to TAVR. 3D TEE images were acquired with a one beat RES (zoom) imaging to achieve high volume rates. The minimum (min) and maximum (max) AA diameter, AA area, perimeter, and other parameters were measured using the eSie Valves package and the standard MDCT method (Figure 7).

In this study all 3D volumes that were acquired and analyzed showed that 3D TEE measurements had excellent correlation with MDCT and excellent agreement between the two methods in selecting the prosthetic aortic valve size according to the standard sizing guidelines (Edwards and Medtronic).¹⁰ They reported some underestimation of the minimum diameter and overestimation of the maximum diameter. Importantly, the mean diameter, annular area, and perimeter were not significantly different. They also reported low intra- and inter-observer variability and good interclass correlation coefficient (ICC), except for maximum diameter. The Kappa between methods was 0.84 for 3D TEE and MDCT.

Ngernsritraku et al.¹⁰ concluded that the eSie Valves package provides accurate and reproducible automated aortic annular measurements in echo and have good agreement in selecting the same valve size as MDCT.

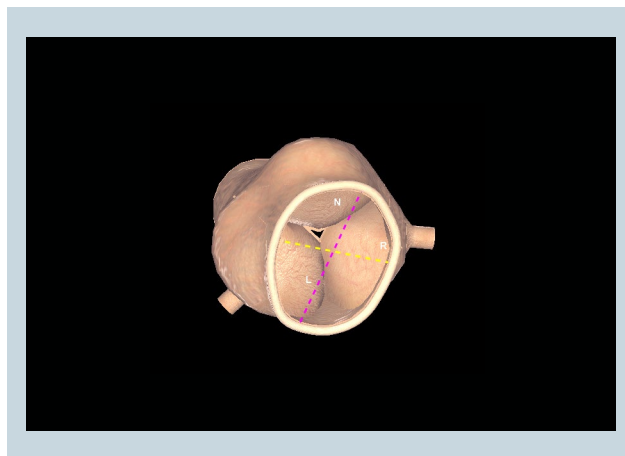


Figure 7. Aortic annulus diameter measurements derived from an aortic valve model calculated by the eSie Valves Package

3.2. Surgical Mitral Valve Repair

Mitral valve repair can involve multiple surgical modifications of the diseased valve to re-establish a quasi-normal physiology: leaflet resection to remove the excess of tissue; annuloplasty to reshape the mitral valve annulus and recover a physiological dimension; chordae displacement/suturing to restore mitral valve tenting. All these operations require planning and significant surgical expertise.

With the eSie Valves package, quantitative planning becomes possible. By modeling the mitral valve in minutes, key measurements specifically designed for surgical planning become instantly available (e.g., mitral valve annulus circumference, intercommissural distance, leaflet areas, regurgitation orifice area), thus facilitating planning and device-size decisions. Noack and colleagues¹¹ analyzed the feasibility and reproducibility of quantitative, 4D mitral valve assessment using the eSie Valves package. On a cohort of 19 cases, the authors reported high measurement reliability, in particular during diastole. Systolic measurement of intercommissural distance was reported to be more challenging as these landmarks are hardly visible when the valve is closed. Overall, the authors concluded that the eSie Valves package could provide fast, excellent, and comprehensive visualization and quantification of mitral valve morphology and dynamics, with high levels of reliability and reproducibility.

Recently, the clinical community started to investigate how mitral valve repair planning could benefit from the eSie Valves package. Using a cohort of N=94 subjects,¹² authors in a recent study showed that body-surface indexed MV annulus circumference correlated with indexed annuloplasty band size ($r = 0.74$) (Figure 8), while P2 segment length and area best discriminated the need for resection (data for 33 cases of the cohort). A similar study was previously conducted where the authors confirmed on a different cohort of 27 patients that mitral annulus circumference was a good predictor of ring size, along with intercommissural distance ($r=0.83$ and 0.80 respectively, all measurements were indexed by body surface area) (Figure 9).¹³

These recent clinical results illustrate the potential benefit of the eSie Valves package for mitral valve repair. The ability to choose device sizing or identify the leaflet area to resect on pre-operative imaging could potentially make the intervention more efficient. More clinical studies are necessary to confirm these early results.

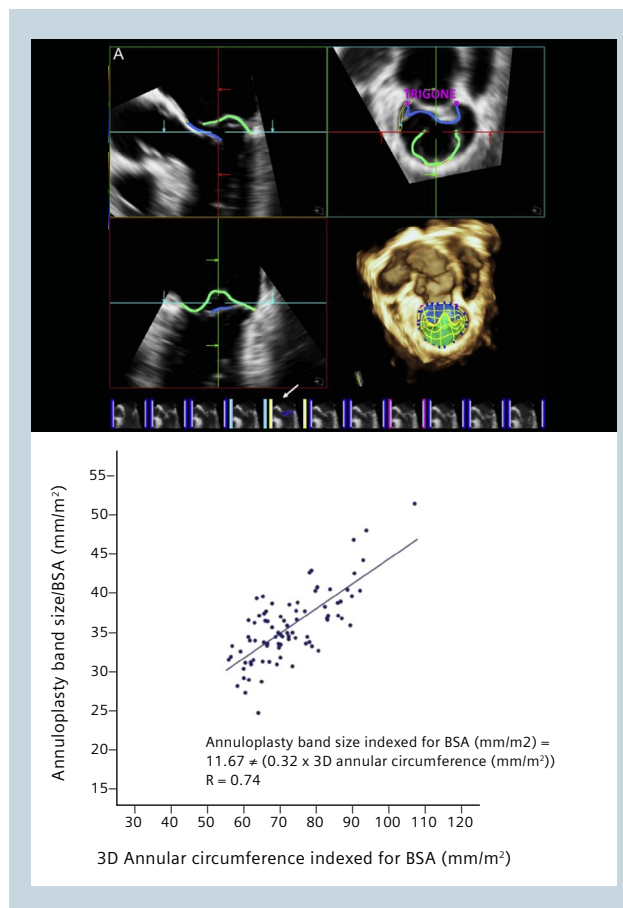


Figure 8. Top panel: Mitral valve model on a patient suffering from posterior prolapse. Bottom panel: Pair-wise correlation between indexed mitral valve circumference and annuloplasty band size¹².

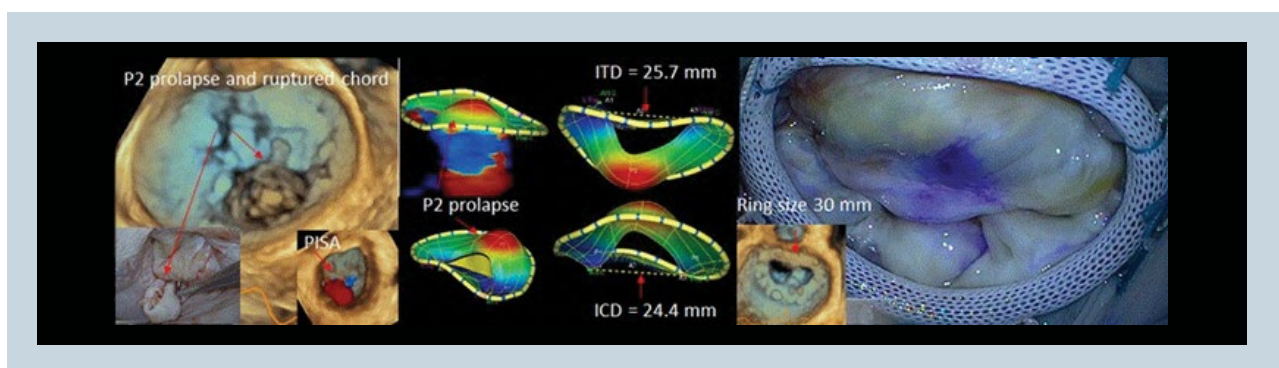


Figure 9. From left to right: Pre-operative imaging of a mitral valve suffering from severe posterior prolapse; eSie Valves package model of the valve, with a clearly identified P2 prolapse. Intertrigonal (ITD) and intercommissural (ICD) distances are highlighted; photo of the annuloplasty ring implanted in the patient and the TEE post-operative image. Pre-operative ICD showed highest predictive power of ring size. Image courtesy of Dr. Mani Vannan.

3.3. Interventional Mitral Valve Therapy

Following the success of TAVR, transcatheter mitral valve repair/replacement (TMVR) methods are being developed as alternatives to open-heart surgeries. The first device to receive regulatory clearance is the MitraClip™ from Abbott. Inspired by Alfieri’s stitch method,¹⁴ the clip uses a catheter to attach the two mitral leaflets together at the regurgitant hole. Placing a MitraClip requires image-based planning to identify the location of clipping and guidance. As illustrated in Figure 10, the Siemens Z6Ms probe allows comprehensive 3D visualization of the mitral valve apparatus physiology (anatomy and blood flow) along with the device, a key requirement for MitraClip interventions.¹⁵ eSie Valves then enables the user to efficiently calculate key measurements during and just after insertion. The operator can directly quantify the effects of the therapy on valve physiology (e.g., anatomical regurgitant orifice, residual regurgitation) and decide if more clipping is necessary to complete the repair, as recently evaluated on a cohort of 10 cases.¹⁶

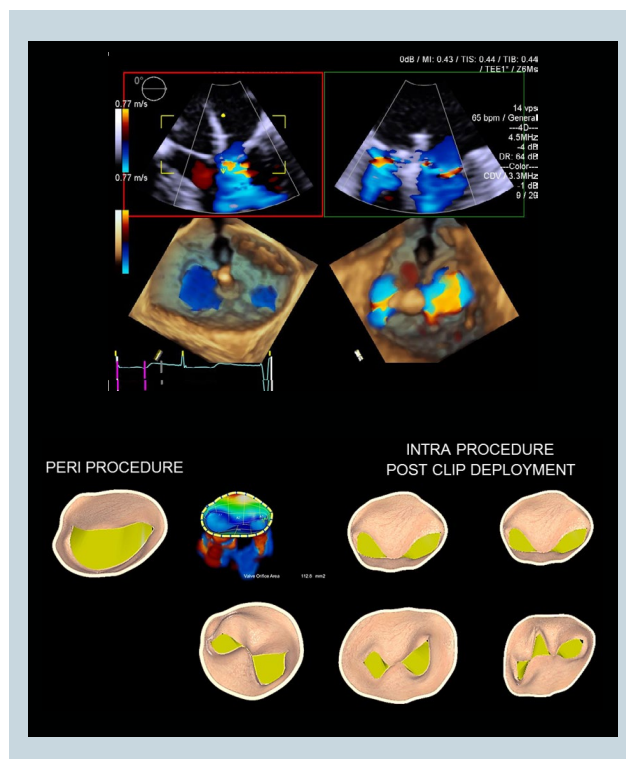


Figure 10. Top panel: 3D real-time visualization of the mitral valve with a MitraClip device installed. One can see the typical two jets during diastole typical of MitraClip repairs. Bottom panel: eSie Valve models of a mitral valve prior to and after MitraClip deployments. With the eSie Valves package, one can model valves with several MitraClips, while visualizing the valve-flow interaction with the typical double-jet diastole pattern post MitraClip.

3.4. Other Applications

Mitral Valve Stenosis

The eSie Valves package is not limited to the applications presented in the previous sections but can be applied to any left heart valve diseases. In Figure 11 for instance, the eSie Valves package was used to quantify the diastolic mitral valve orifice area (MVOA) in a patient suffering from mitral stenosis (MVOA = 137 mm²). Since the algorithms featured in the eSie Valves package were trained on a large database of annotations covering multiple diseases, they could automatically detect the leaflets despite the disease and, after minor editing, provide a comprehensive 3D model of the diseased valve for therapy planning.

Rheumatic Valve Disease

Rheumatic fever, an autoimmune reaction to a streptococcal infection, can affect the heart and, in particular, mitral valve leaflets, with an increased load of fibrosis resulting in stenosis and regurgitation. Figure 12 shows a 3D B-Mode acquisition of the mitral valve in a patient suffering from the condition, at peak diastole, with quantified valve model (MVOA = 306 mm²).

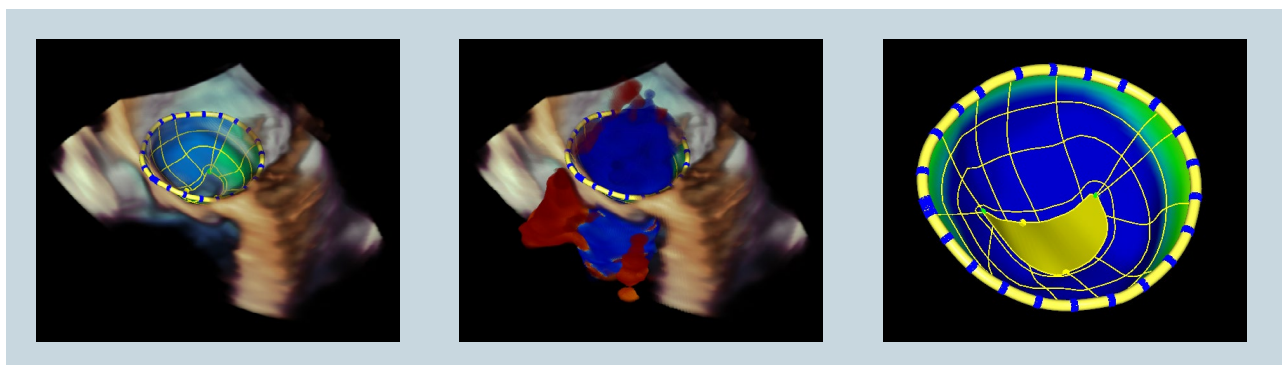


Figure 11. Quantification of mitral valve orifice area in a stenosis case. The eSie Valves package allows users to clearly see the restricted posterior leaflet motion and quantify the resulting, impaired mitral valve orifice.

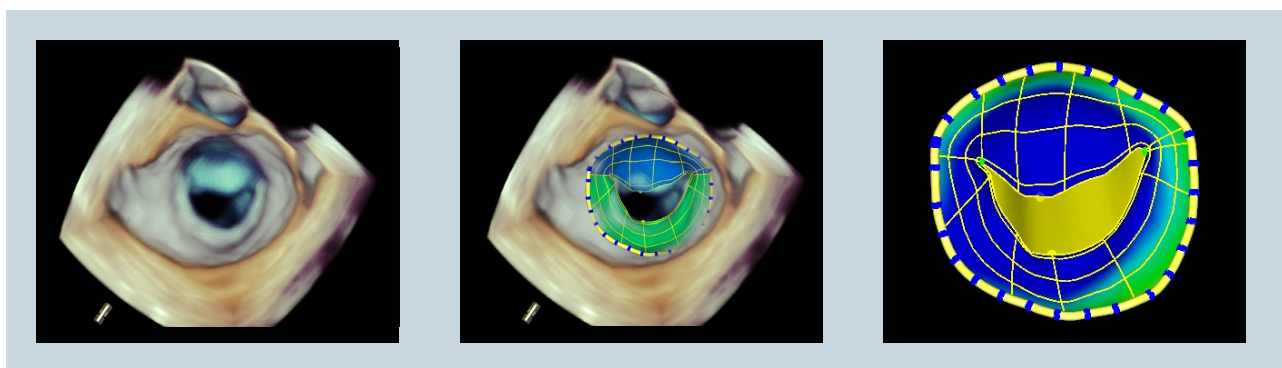


Figure 12. 3D B-Mode and mitral valve model in a patient suffering from rheumatic mitral valve disease. Calculated mitral valve orifice area was 306 mm².

Barlow's Mitral Valve Disease

Barlow's disease is characterized by a pronounced posterior leaflet prolapse, accompanied by leaflet thickening, excessive leaflet tissue, chordae elongation or rupture, and severe dilation of the mitral valve annulus. Patients with Barlow's disease suffer from mitral valve regurgitation, which can be corrected only through surgical mitral valve repair. These procedures are complex, as they require reducing the annulus size, resecting the excess of tissue, and adjusting the chordae. Identifying the segments responsible for the regurgitation and quantifying the features of the valve anatomy are important elements of therapy planning. Figure 13 illustrates a joint B-Mode/Color Doppler acquisition of the mitral valve in a patient suffering from the condition. Coupled with the model estimated by the eSie Valves package, the surgeon can identify the location of the regurgitant jet and key features of the mitral valve anatomy. In this patient, the eSie Valves package calculated a posterior prolapse volume of 1.5 ml (Figure 14, left), a flail gap (A2P2 segment) of 5.5 mm (Figure 14, right), and an average annulus diameter of 47 mm. Despite the complexity of the disease, the eSie Valves package's robust algorithm, coupled with intuitive editing, enables quantification of the mitral valve anatomy even in complex cases.

Aortic Valve Regurgitation and Dilated Aortic Root

Figure 15 illustrates how the eSie Valves package can be used to quantify the aortic valve function in a patient suffering from aortic regurgitation and dilated aortic root. Using the real-time 3D color Doppler imaging, the aortic regurgitation can be perfectly observed. The eSie Valves package is then applied to model the aortic system and measure key features of the valve, like the diameters at the aortic annulus (26 mm is the average for this patient) and the sinotubular junctions.

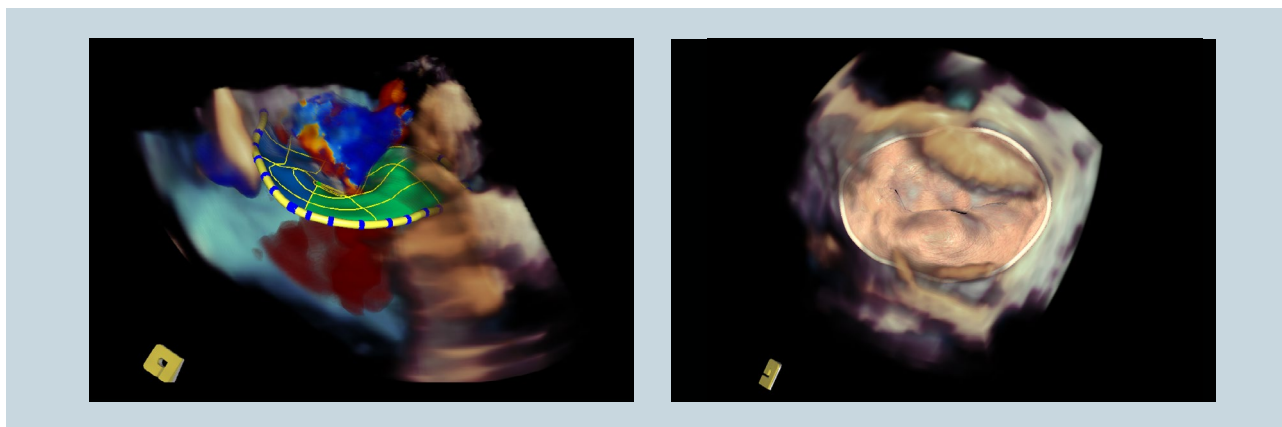


Figure 13. Left: Simultaneous B-Mode and Color Doppler images of a mitral valve in a patient suffering from Barlow's disease. One can clearly see the regurgitant jet. Right: Realistic rendering of the model estimated with the eSie Valves package, exhibiting typical features of Barlow's disease: posterior prolapse, enlarged annulus.

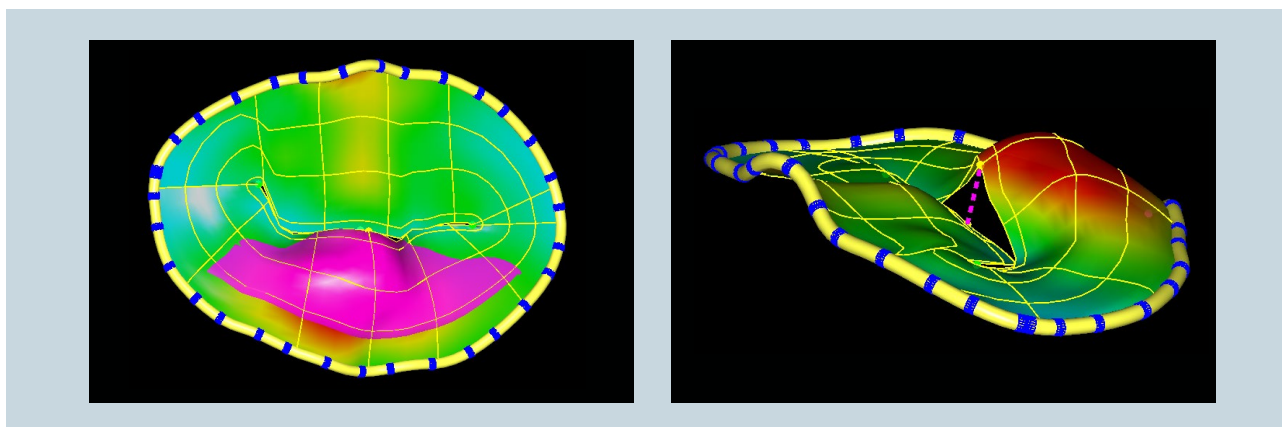


Figure 14. Left: Quantification of posterior prolapse volume (in pink). Right: Quantification of posterior flail gap, with visual cues (dotted pink line) to highlight where the flail gap is measured.

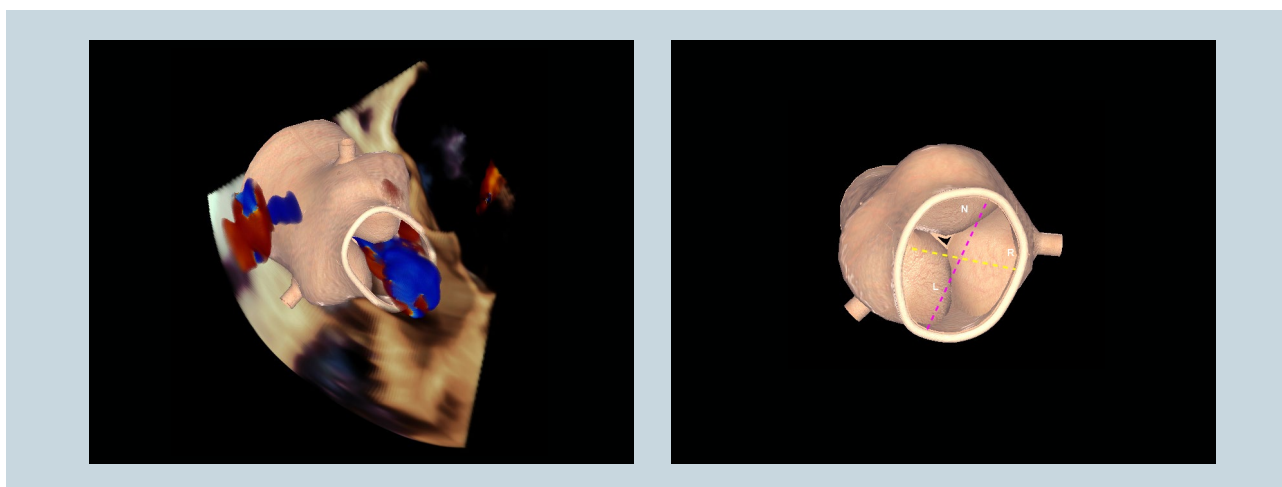


Figure 15. Quantification of aortic root annulus in a patient suffering from aortic regurgitation and dilated aortic root.

Conclusion

The True Volume TEE transducer (Z6Ms) combined with the eSie Valves package is potentially the new gold standard for visualization and quantification during valve interventions and surgeries. The True Volume TEE transducer defines the leading edge of 4D imaging by offering simultaneous, real time, and high frame rate imaging of heart anatomy and blood flow without stitching multiple heartbeats together. Being able to see every beat in real time without stitching is crucial, especially for patients with arrhythmias.

The eSie Valves package offers a comprehensive analysis of the mitral and aortic valves with one click of a button for accurate and efficient quantification. The True Volume TEE transducer also offers advanced thermal management to transport heat away from the array to minimize interruption due to transducer overheating. The Z6Ms is also fully shielded to minimize EMI interference and thus offers uninterrupted imaging, higher sensitivity, and higher volume rates for a much wider range of clinical procedures. The True Volume TEE transducer paired with the powerful eSie Valves package offers a comprehensive clinical solution that seamlessly combines imaging and quantification with the click of a button.

References

- ¹Roger VL, Go AS, Lloyd-Jones DM, Benjamin EJ, Berry JD, Borden WB, Bravata DM, et al. Heart Disease and Stroke Statistics—2011 Update. *Circulation*. 2011;123: e18-e209.
- ²Nishimura R, Otto C, Bonow R, Carabello B, Erwin J, Guyton R, O’Gara P, et al. 2014 AHA/ACC guideline for the management of patients with valvular heart disease: a report of the American College of Cardiology/American Heart Association Task Force on Practice Guidelines. *Journal of the American College of Cardiology*. 2014; 63(22): e57-e185.
- ³Choi J, Georgescu B, Ionasec R, Raman S, Hong G, Liu S, Houle H, Vannan M. Novel Semi-Automatic Quantitative Assessment of the Aortic Valve and Aortic Root from Volumetric 3D Echocardiography: Comparison to Volumetric Cardiac Computed Tomography. *Circulation*. 2008;118:S_103-S_104.
- ⁴Gassner E, Ionasec R, Georgescu B, Vogt S, Schoepf U, Comaniciu D. Performance of a Dynamic Aortic Valve Model for Quantification of the Opening Area at Cardiac MDCT Comparison to Manual Planimetry. *Radiological Society of North America*; 2008 Dec 5 [cited 2015 Nov 20]. Available from: <http://archive.rsna.org/2008/6011906.html>.
- ⁵Ionasec R, Georgescu B, Comaniciu D, Vogt S, Schoepf U, Gassner E. Patient-specific 4D Aortic Root Models Derived from Volumetric Image Data Sets. *Radiological Society of North America*; 2008 Dec 5 [cited 2015 Nov 20]. Available from: <http://archive.rsna.org/2008/6022710.html>.
- ⁶Ionasec R, Voigt I, Georgescu B, Wang Y, Houle H, Vega-Higuera F, Navab N, Comaniciu D. Patient-specific modeling and quantification of the aortic and mitral valves from 4-D cardiac CT and TEE. *IEEE Transactions on Medical Imaging*. 2010;9: 1636-1651.
- ⁷Sasa G, Ionasec R, Vitanovski D, Voigt I, Wang Y, Georgescu B, Navab N, Comaniciu D. Complete valvular heart apparatus model from 4D cardiac CT. *Medical image analysis*. 2012;16(5): 1003-1014.
- ⁸Yefeng Z, Barbu A, Georgescu B, Scheuering M, Comaniciu D. Four-chamber heart modeling and automatic segmentation for 3D cardiac CT volumes using marginal space learning and steerable features. *IEEE Transactions on Medical Imaging*. 2008;11: 1668-1681.
- ⁹Tu Z. Probabilistic boosting-tree: Learning discriminative models for classification, recognition, and clustering. *Computer Vision, 2005. ICCV 2005. Tenth IEEE International Conference*. 2005; 2: 1589-1596.
- ¹⁰Ngernsritraku T, Hur D, McDade K, Kaplan R, Houle H, Lin B, Vaitkevecuite I, Cleman M, Mangi A, Forrest J, Sugeng L. Aortic Annulus Sizing Using A Novel Automated Method: Can Echo Select the Correct Valve Size? *American Society of Echocardiography*. 2015.
- ¹¹Noack T, Mukherjee C, Kiefer P, Emrich F, Vollroth M, Ionasec R, Voigt I, et al. Four-dimensional Modelling of the Mitral Valve by Real-time 3D Transoesophageal Echocardiography: Proof of Concept. *Interactive cardiovascular and thoracic surgery*. 2015;20(2): 200-208.
- ¹²Reprinted from *Journal of the American Society of Echocardiography*, 9/28, Calleja A, Poulin F, Woo A, Meineri M, Jedrzkiewicz S, Vannan M, Rakowski H, David T, Tsang W, Thavendiranathan P., Quantitative Modeling of the Mitral Valve by Three-Dimensional Transesophageal Echocardiography in Patients Undergoing Mitral Valve Repair: Correlation with Intraoperative Surgical, 10083-92, 2015 with permission from Elsevier. <http://www.sciencedirect.com/science/article/pii/S0894731715003120>.
- ¹³Liu S, Milla F, Kauten J, Sayegh H, Polsani V, Mobasseri S, Zhou X, Qian Z, Mansi T, Houle H, Martin R, Vannan M, Predicting Ring Size using Real-time Automated Quantitative Three-Dimensional Transesophageal Echocardiography in Surgical Mitral Valve Repair, AHA abstract, submitted.
- ¹⁴Alfieri O, Maisano F, De Bonis M, Stefano P, Torracca L, Oppizzi M, La Canna G. The double-orifice technique in mitral valve repair: a simple solution for complex problems. *Journal of Thoracic and Cardiovascular Surgery*. 2001;122(4): 674-681.
- ¹⁵Lancellotti P, Zamorano J, Vannan M. Imaging Challenges in Secondary Mitral Regurgitation Unsolved Issues and Perspectives. *Circulation: Cardiovascular Imaging*. 2014;7(4): 735-746.
- ¹⁶Liu S, Rajagopal V, Ballard W, Mobasseri S, Polsani V, Sayegh H, Milla F, Zhou X, Qian Z, Martin R, Mansi T, Houle H, Vannan M. Evaluation of Immediate Procedural Outcome after MitraClip Using Automated Quantitative Real-Time Volume Color Flow Doppler Transesophageal Echocardiography. AHA abstract. 2015 Nov [cited 2015 Nov 20]. Available from: http://circ.ahajournals.org/content/132/Suppl_3/A16905.short.

Recognitions

The eSie Valves package and related technologies received the following international recognitions:

- 2015 R&D 100 Award received in Las Vegas, Nevada for “eSie Valves™ advanced analysis package”.
- NJ Alva Edison Patent Award 2015 for the patent “Valve treatment simulation from medical diagnostic imaging data.” US8920322 B2.
- Front cover of the Journal of The American Society of Echocardiography, September 2015 (Volume 28, Issue 9, ISSN 0894-7317) for the article “Quantitative Modeling of the Mitral Valve by Three-Dimensional Transesophageal Echocardiography in Patients Undergoing Mitral Valve Repair: Correlation with Intraoperative Surgical Technique.” Anna Calleja, Frédéric Poulin, Anna Woo, Massimiliano Meineri, Sean Jedrzkiewicz, Mani A. Vannan, Harry Rakowski, Tirone David, Wendy Tsang, Paaladinesh Thavendiranathan.
- MICCAI 2010, Young Scientist Award, for the paper “Complete valvular heart apparatus model from 4D cardiac CT.” Saša Grbić, Razvan Ionasec, Dime Vitanovski, Ingmar Voigt, Yang Wang, Bogdan Georgescu, Nassir Navab, and Dorin Comaniciu. In Medical Image Computing and Computer-Assisted Intervention–MICCAI 2010, pp. 218-226. Springer Berlin Heidelberg, 2010.
- MICCAI 2011, Young Scientist Award, for the paper “Towards patient-specific finite-element simulation of MitraClip procedure.” Tommaso Mansi, Ingmar Voigt, E. Assoumou Mengue, R. Ionasec, Bogdan Georgescu, Thilo Noack, Joerg Seeburger, and Dorin Comaniciu. In Medical Image Computing and Computer-Assisted Intervention–MICCAI 2011, pp. 452-459. Springer Berlin Heidelberg, 2011.
- Based on 50+ Siemens patents and patent applications.



On account of certain regional limitations of sales rights and service availability, we cannot guarantee that all products included in this brochure are available through the Siemens sales organization worldwide. Availability and packaging may vary by country and is subject to change without prior notice. Some/All of the features and products described herein may not be available in the United States.

The information in this document contains general technical descriptions of specifications and options as well as standard and optional features, which do not always have to be present in individual cases.

Siemens reserves the right to modify the design, packaging, specifications, and options described herein without prior notice. Please contact your local Siemens sales representative for the most current information.

Note: Any technical data contained in this document may vary within defined tolerances. Original images always lose a certain amount of detail when reproduced.

eSie Valves is a trademark of Siemens Medical Solutions USA, Inc.

MitraClip is a trademark of Abbott Group of Companies.

Siemens Healthcare Headquarters

Siemens Healthcare GmbH
Henkestr. 127
91052 Erlangen
Germany
Phone: +49 9131 84-0
siemens.com/healthcare

Legal Manufacturer

Siemens Medical Solutions USA, Inc.
Ultrasound
685 East Middlefield Road
Mountain View, CA 94043
USA